# *Giant cell lesions*

# Peripheral giant cell granuloma

## (GIANT CELL EPULIS)

* Occurs exclusively on the **gingiva** or **edentulous alveolar ridge**, presenting as a red or reddish-blue nodular mass.

* Most lesions are **smaller than 2cm** in diameter. Although larger ones are seen occasionally.

* The lesion can be **sessile or pedunculated** and may or may not be ulcerated.

**Peripheral giant cell granuloma: Nodular reddish-purple mass of the maxillary gingiva.**

**Peripheral giant cell granuloma: ulcerated mass of the mandibular gingiva.**

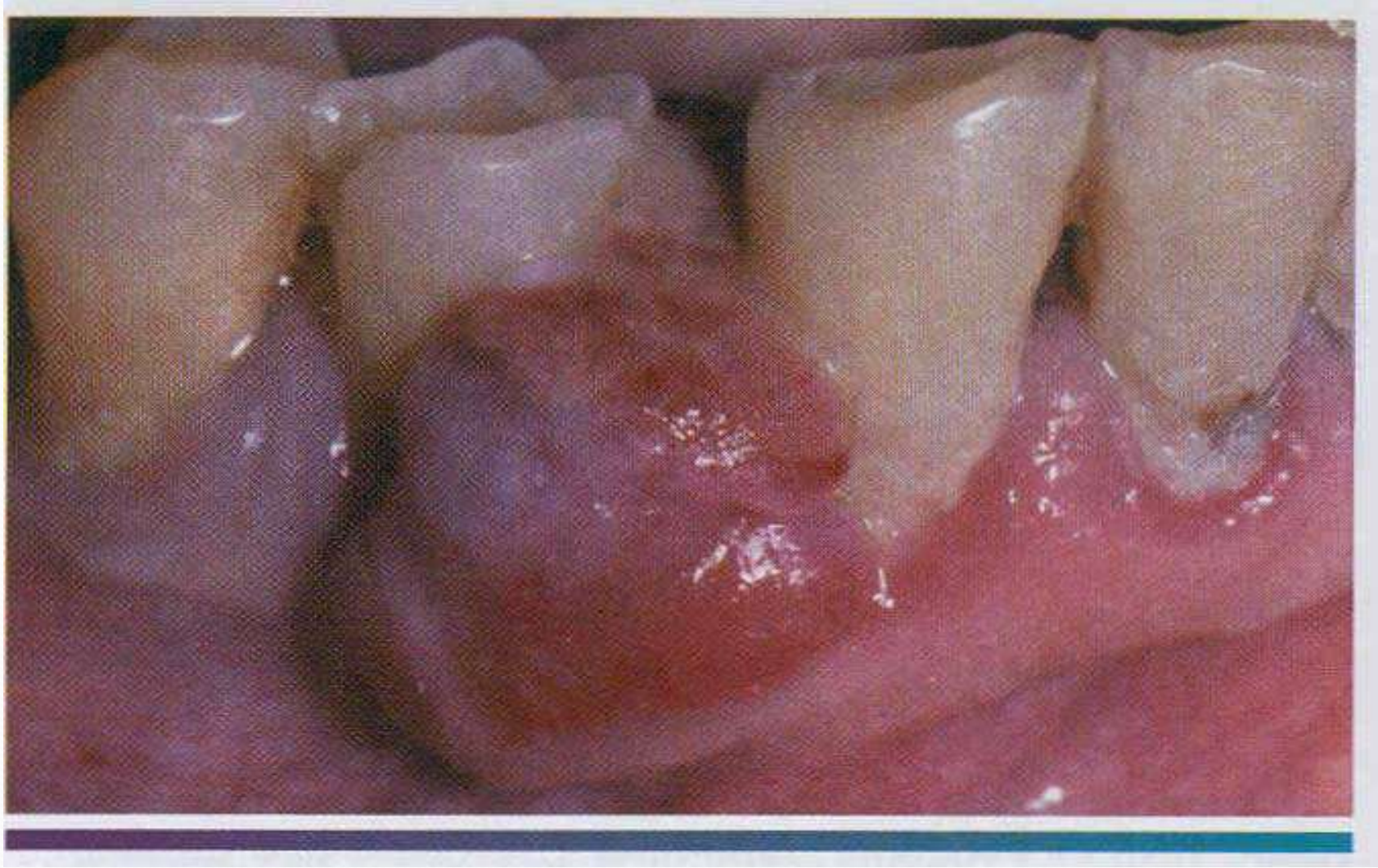

# Histopathologic Features

*The giant cells may contain only a *few nuclei or up to several dozen.* Some of these cells may have large vesicular nuclei, others demonstrate small pyknotic nuclei. Mitotic figures are fairly common in the background mesenchymal cells.

*Abundant **hemorrhage** is characteristically found throughout the mass. Which often results in deposits of hemosiderin pigment.

**Peripheral giant cell granuloma:** **Low-power view showing a nodular proliferation of multinucleated giant cells within the gingiva.**

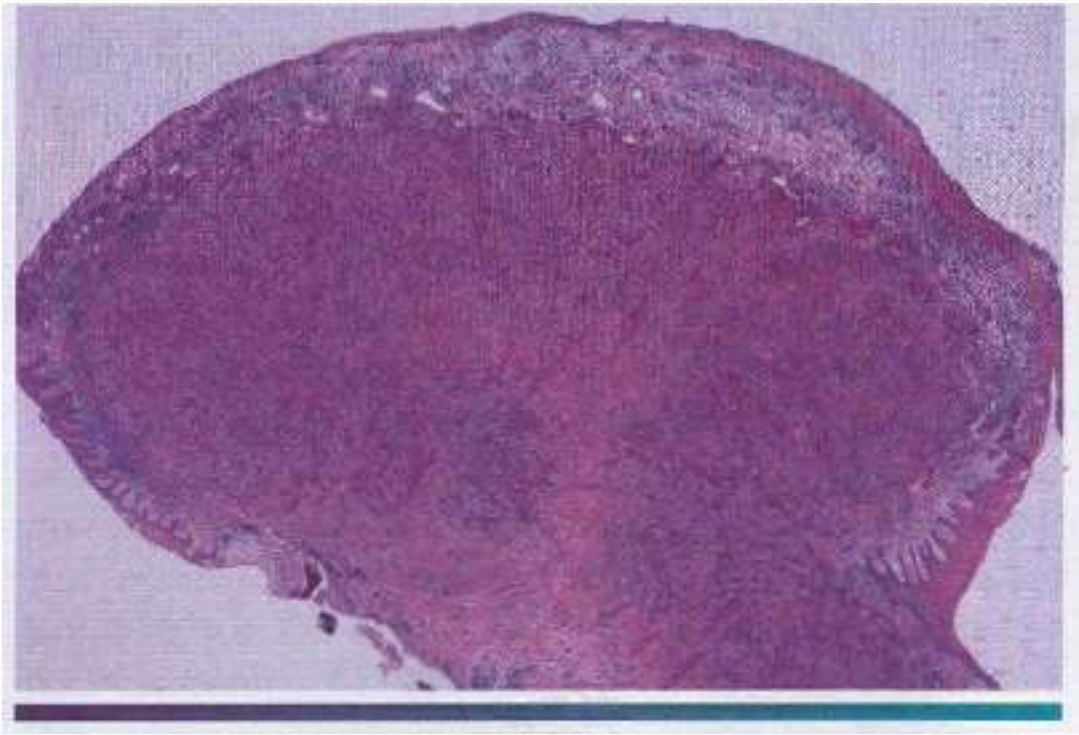

**Peripheral giant cell granuloma:** high-power view showing scattered **multinucleated giant cells** within a hemorrhagic background of ovoid and spindle-shaped mesenchymal cells.

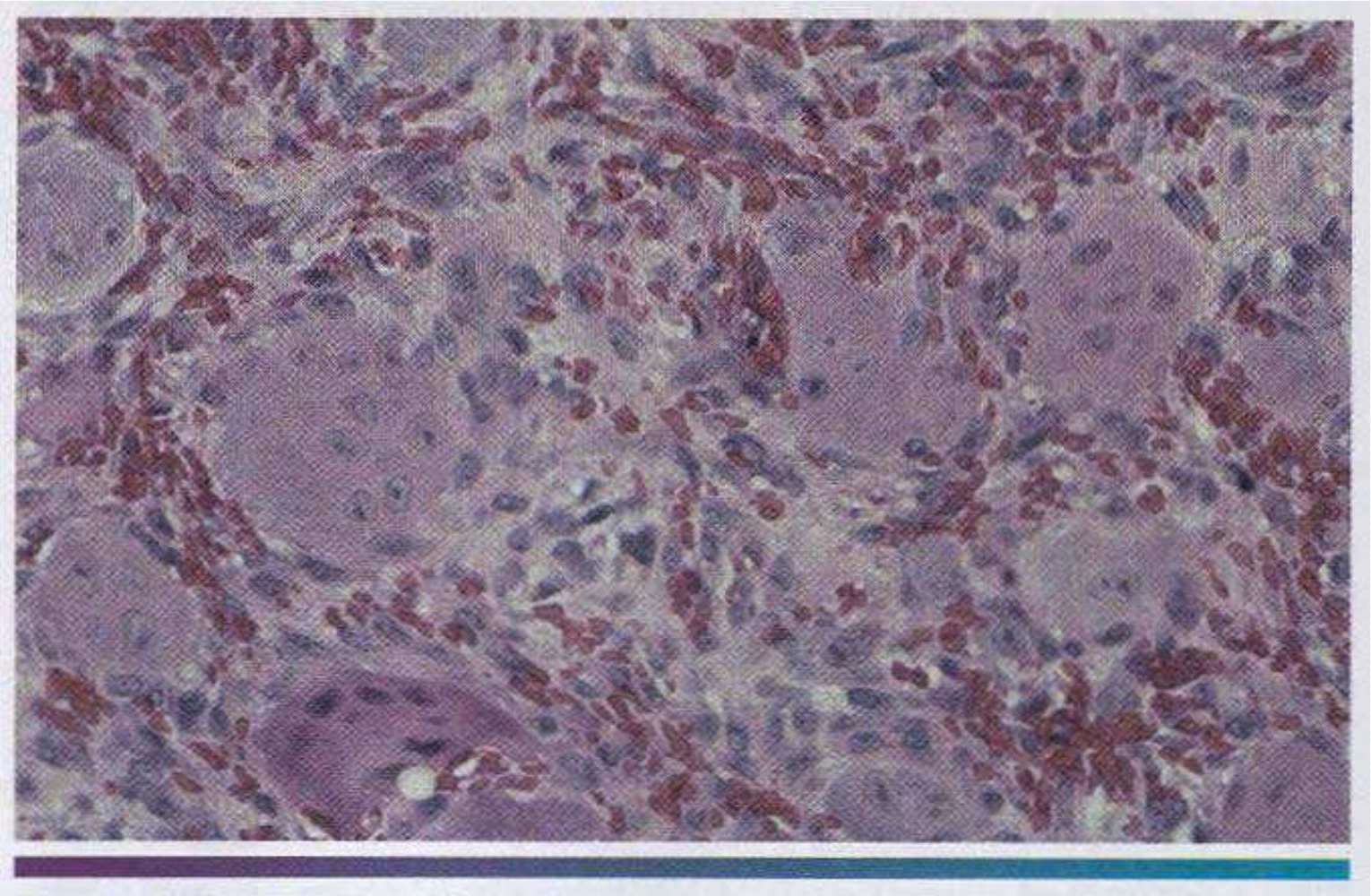

# Central giant cell granuloma (giant cell lesion; giant cell tumor)

Most giant cell granulomas of the jaws are **asymptomatic** and first come to attention during a routine radiographic examination or as a result **of painless expansion** of the affected bone.

# Central giant cell granuloma:

1. **Nonaggressive lesions** make up most cases, exhibit few or no symptoms, demonstrate slow growth, and do not show cortical perforation or root resorption of teeth involved in the lesion.

2. **Aggressive lesions** are characterized by pain, rapid growth. cortical perforation. and root resorption. They show a marked tendency to recur after treatment, compared with the nonaggressive types.

**Central giant cell granuloma:** The occlusal radiograph shows a radiolucent lesion with cortical expansion.

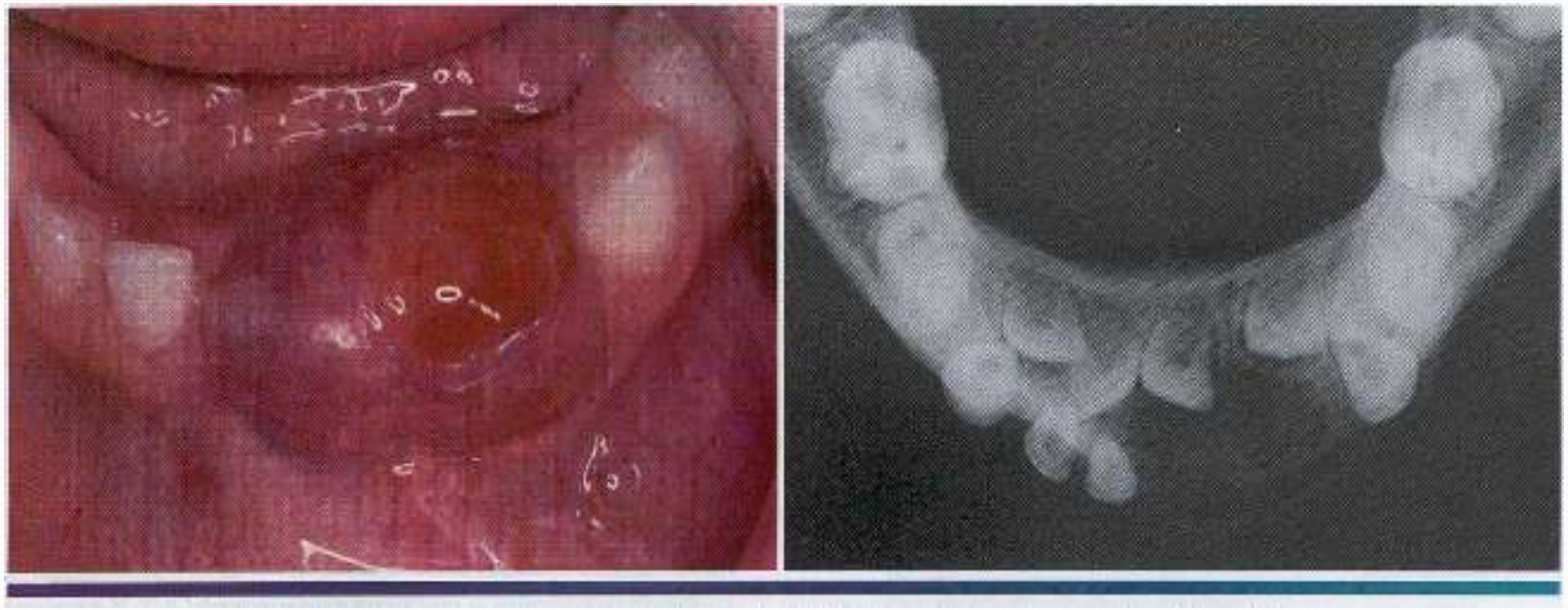

**Central giant cell granuloma:** Panoramic radiograph showing a large,expansile radiolucent lesion in the anterior mandible.

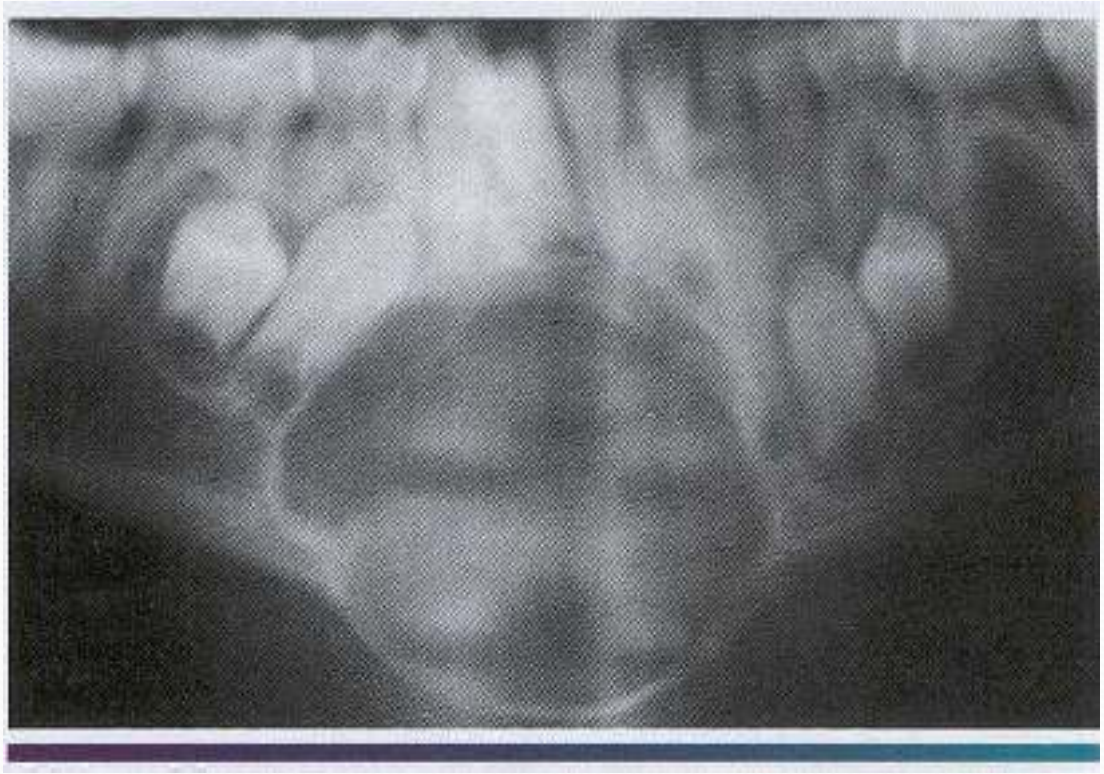

Multilocular giant cell lesions cannot be distinguished radiographically from ameloblastoma or other multilocular lesions.

* **Central giant cell granuloma:** Numerous multinucleated giant cells within a background of plump proliferating mesenchymal cells. Note extensive red blood cell extravasation.

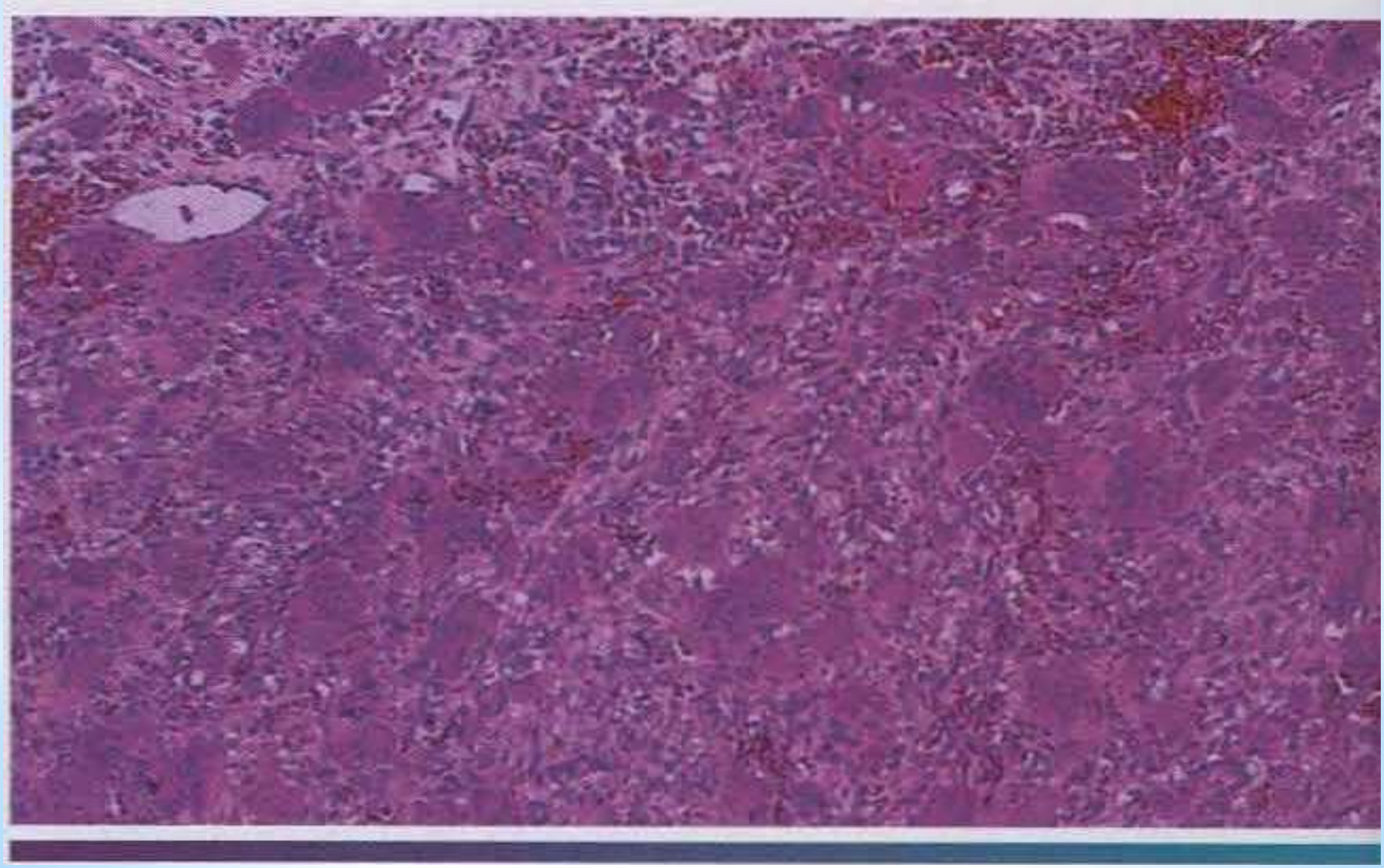

**Cherubism:** is a rare developmental jaw condition that is inherited as an autosomal **dominant** trait with high penetrance but variable expressivity.

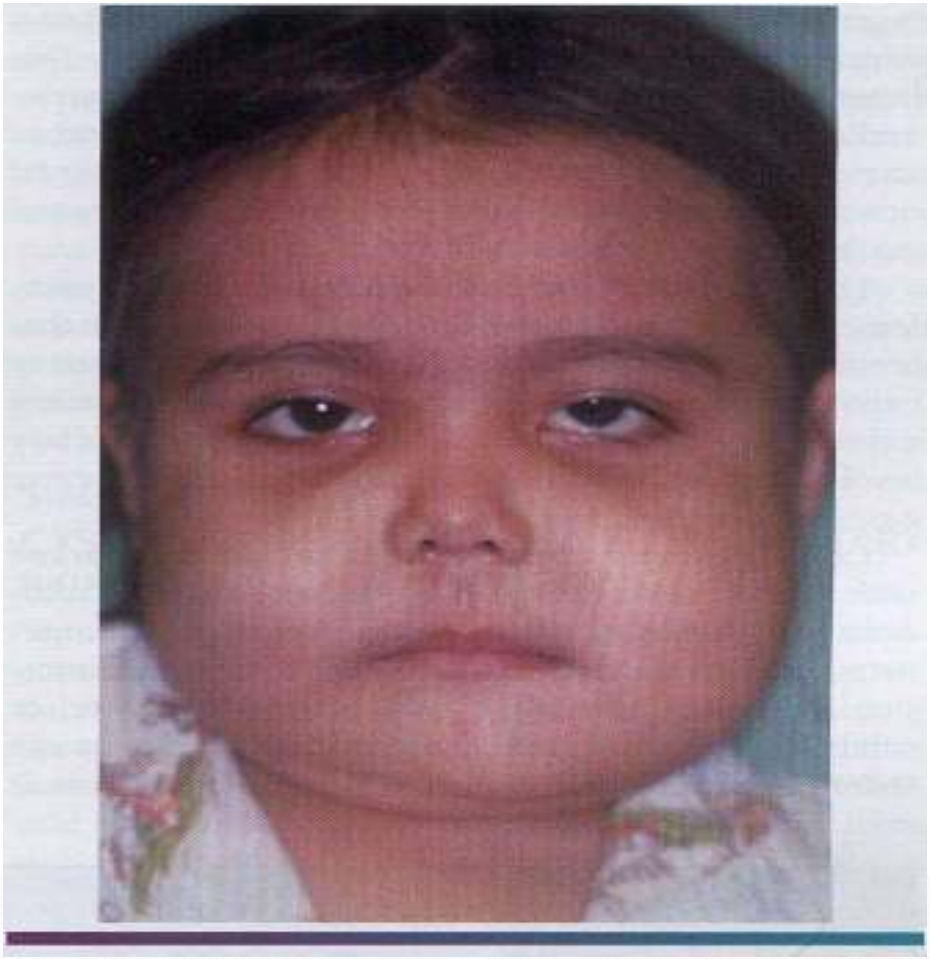

The mandibular lesions typically appear as a pain less, bilateral expansion of the posterior mandible that tends to involve the angles and ascending rami.

The bony expansion is usually **bilaterally symmetrical**

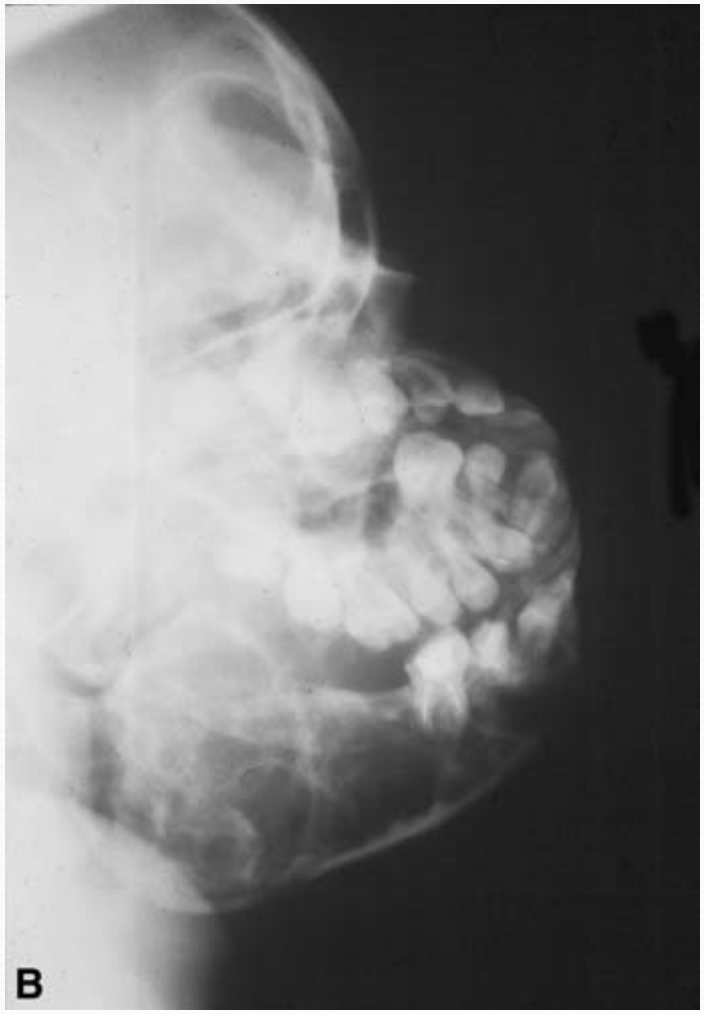

**A: panoramic radiograph** of a 7-year-old white male. Bilateral multilocular radiolucencies can be seen in the posterior mandible.

**B:** same patient 6 years later. The lesions in the mandibular rami demonstrate significant resolution, but areas of involvement are still present in the body of the mandible.

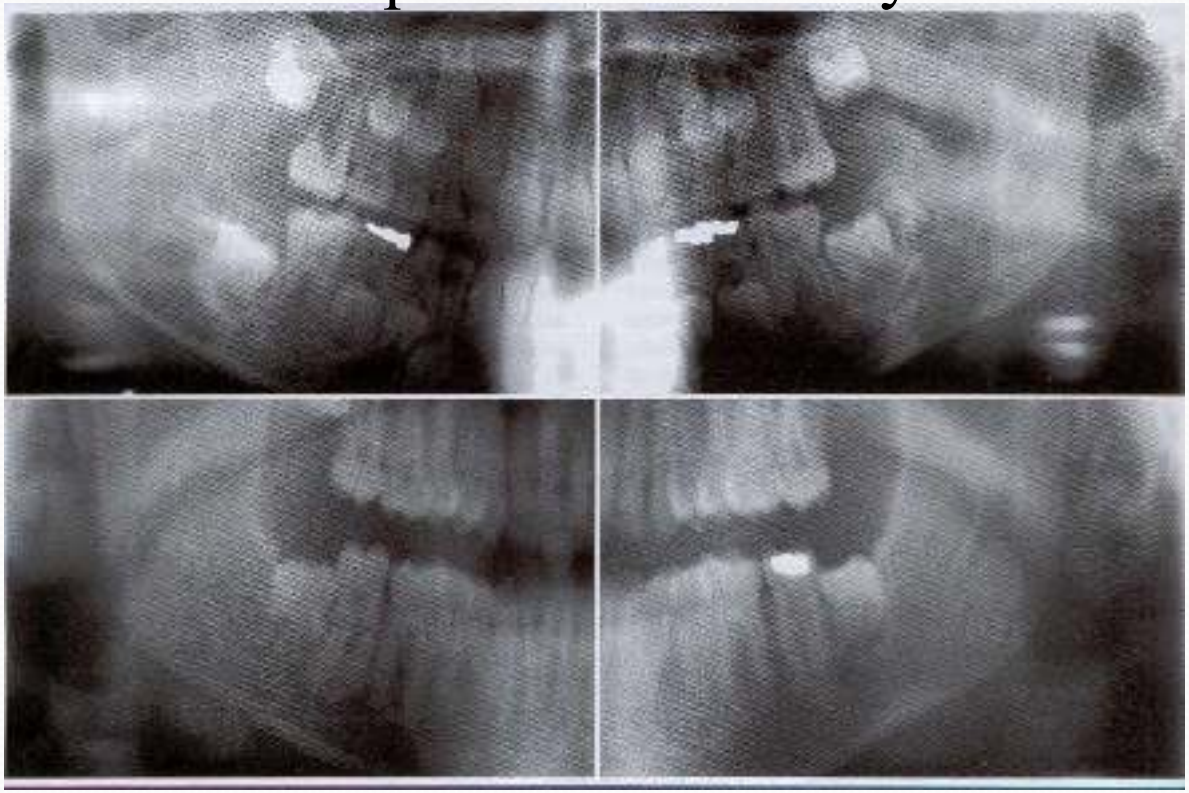

**Cherubism: Showing scattered giant cells within a background of cellular, hemorrhagic mesenchymal tissue. The inset demonstrates perivascular eosinophilic cuffing.**

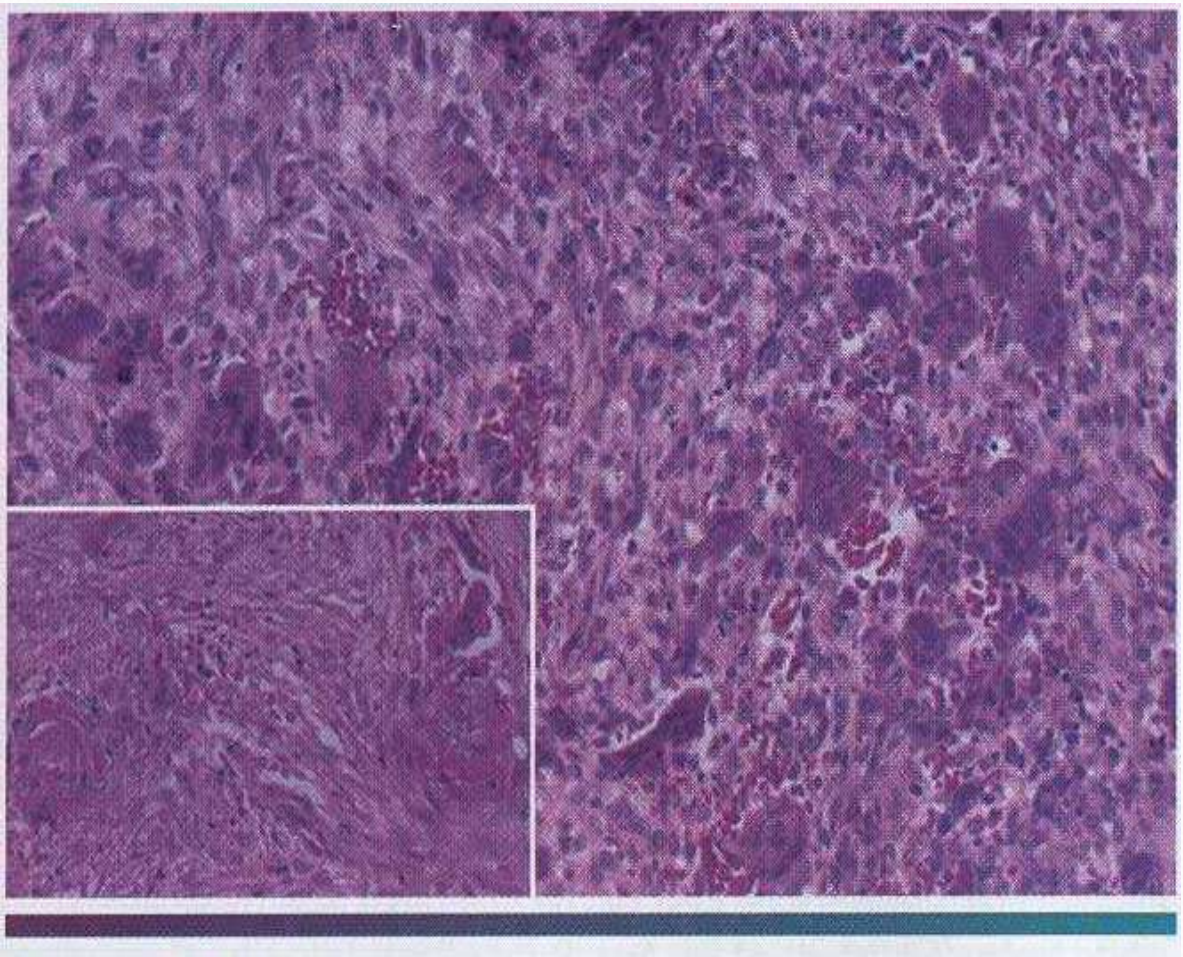

## Aneurysmal bone cyst

is an intraosseous accumulation of variable-sized. Blood filled spaces surrounded by cellular fibrous connective tissue that often is admixed with trabeculae of reactive woven bone.

- Aneurysmal bone cysts are located most commonly in the shaft of a **long bone** or in the **vertebral column** in patients **younger than age 30**.
- **Gnathic aneurysmal** bone cysts are **uncommon**, with approximately **2%** reported from the jaws.

**Aneurysmal bone cyst : A large multilocular radiolucent lesion involves most of the ascending ramus in a 5-years old white boy.**

**Simple bone cyst:** **Panoramic film showing a large multilocular simple bone cyst of the mandible in a 16-year-old white male.**

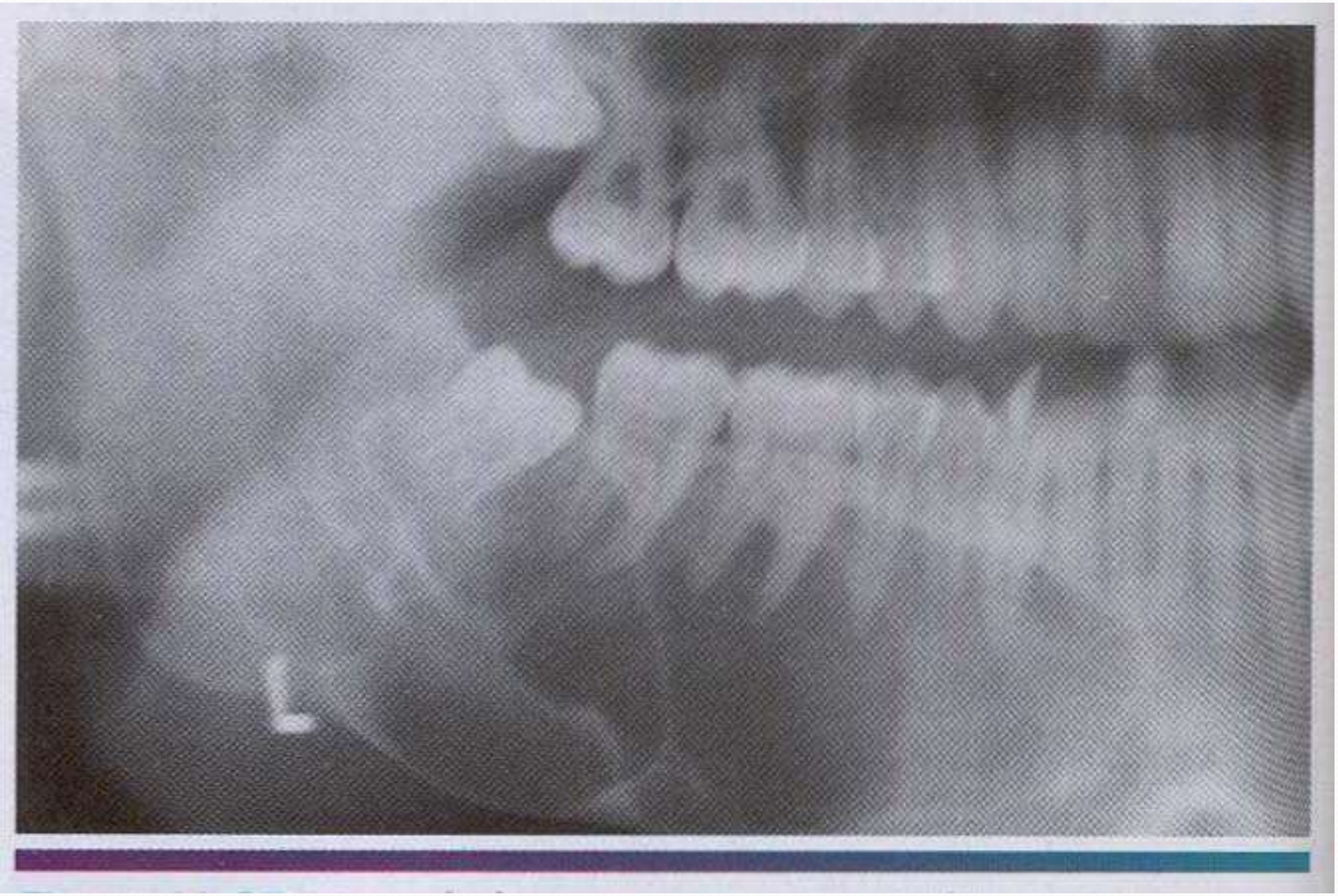

**Simple bone cyst: Periapical radiograph showing a radiolucent area in the apical region of the anterior mandible. The incisor teeth responded normally to vitality testing, and no restorations are present.**

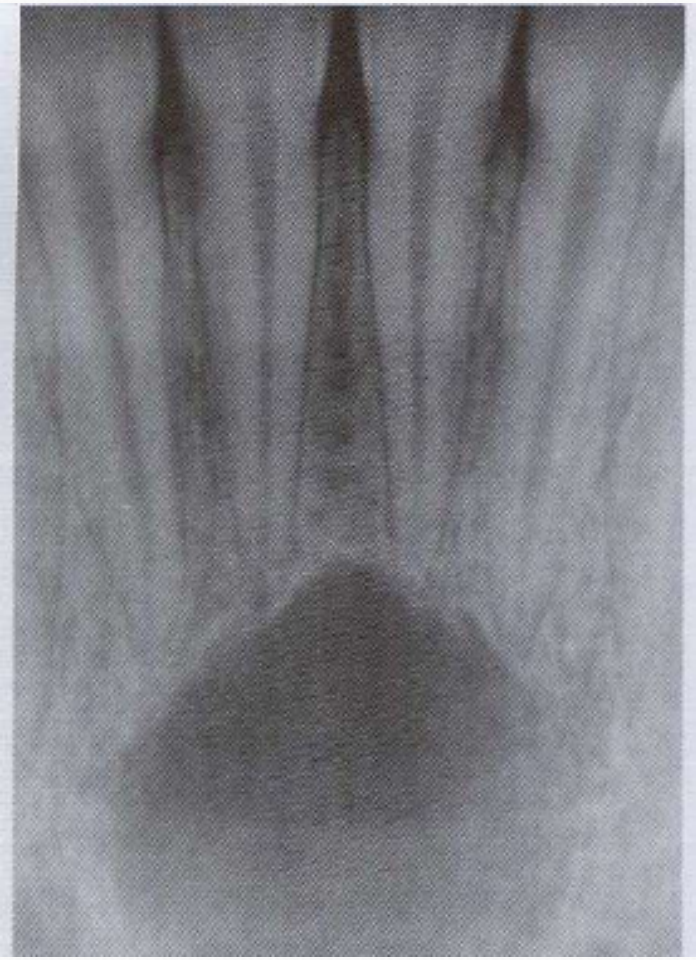

**Aneurysmal bone cyst: Photomicrograph showing a blood-filled space surrounded by fibroblastic connective tissue. Scattered multinucleated giant cells are seen adjacent to the vascular space.**

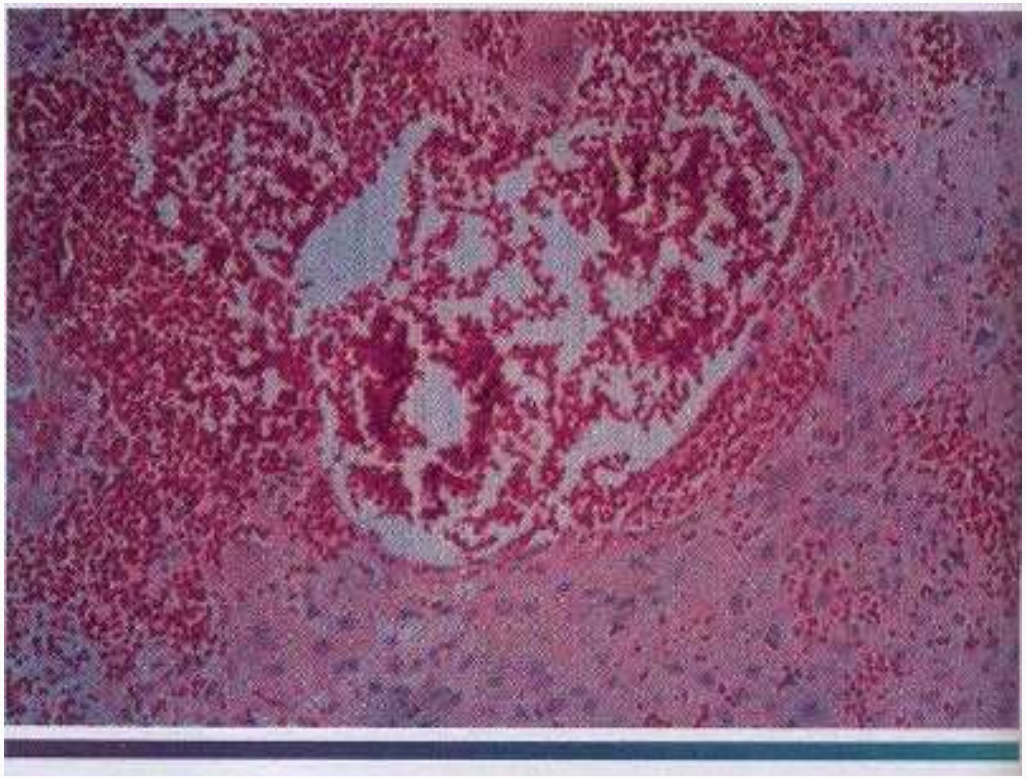

**Simple bone cyst:** **Photomicrograph of the bony wall of a simple bone cyst. A thin. Vascular connective tissue membrane is adjacent to the bone and no epithelial lining is identified.**

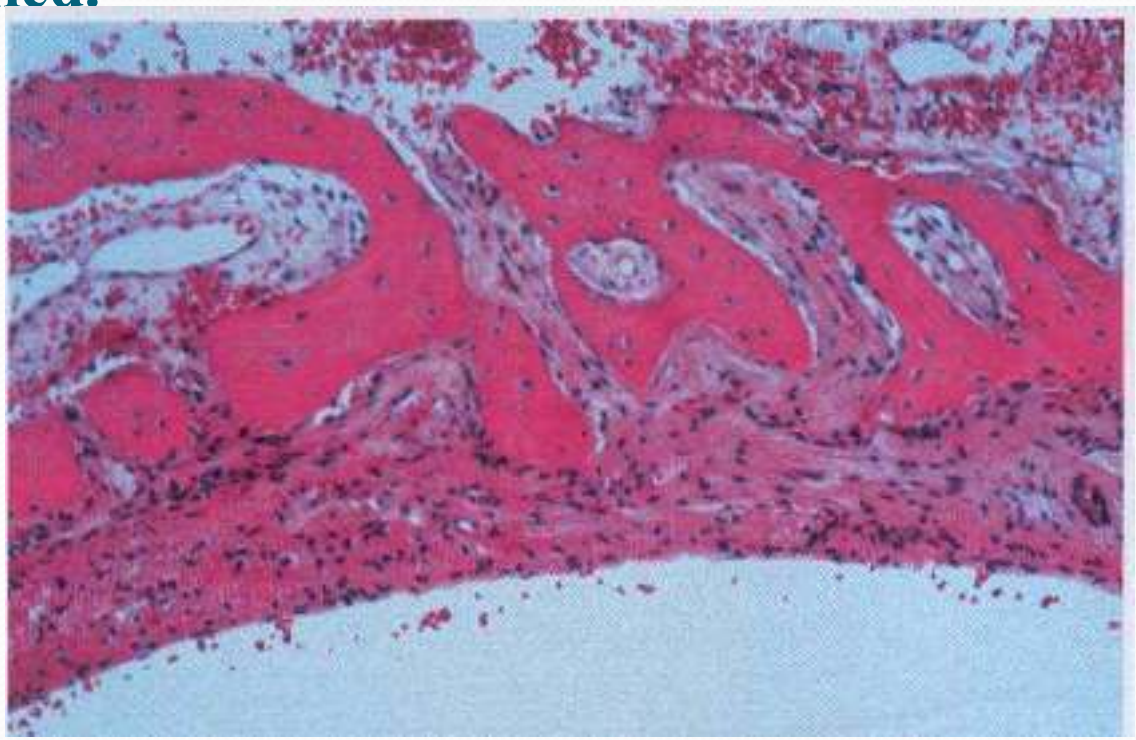

**Hyperparathyroidism:** Palatal enlargement is characteristic of the renal osteodystrophy associated with secondary hyperparathyroidism.

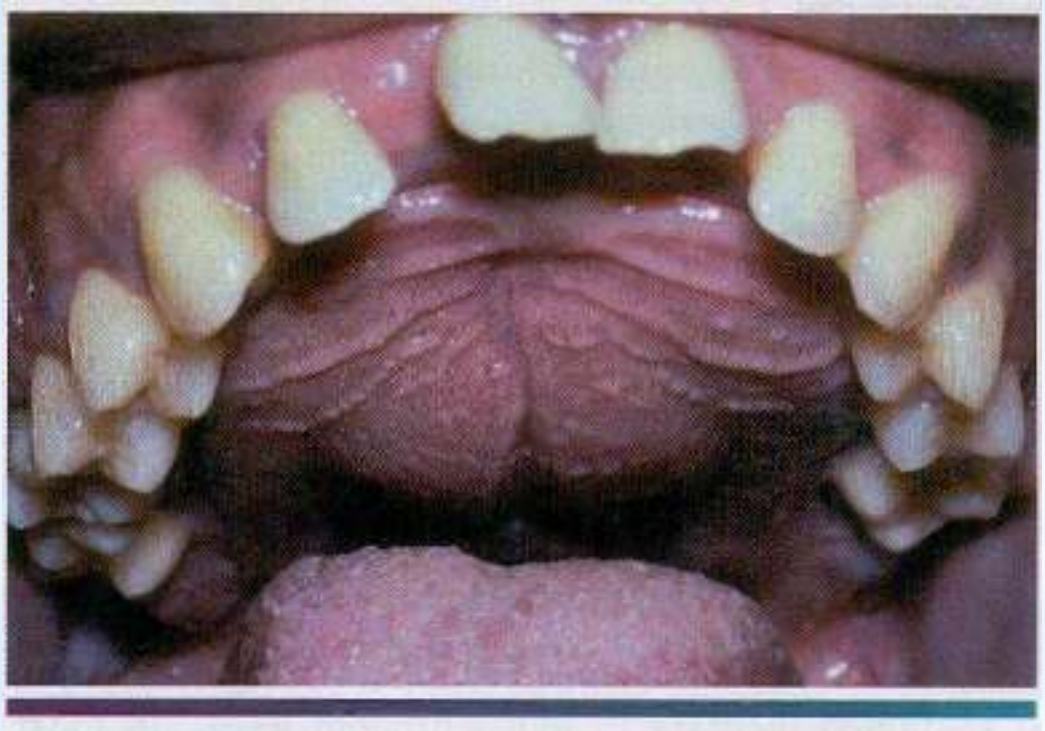

**Hyperparathyroidism: This periapical radiograph reveals the "ground glass" appearance of the trabeculae and loss of lamina dura in a patient with secondary hyperparathyroidism.**

**Hyperparathyroidism:** **High-power photomicrograph of a brown tumor shows scattered multinucleated giant cells within a vascular and proliferative fibroblastic background.**

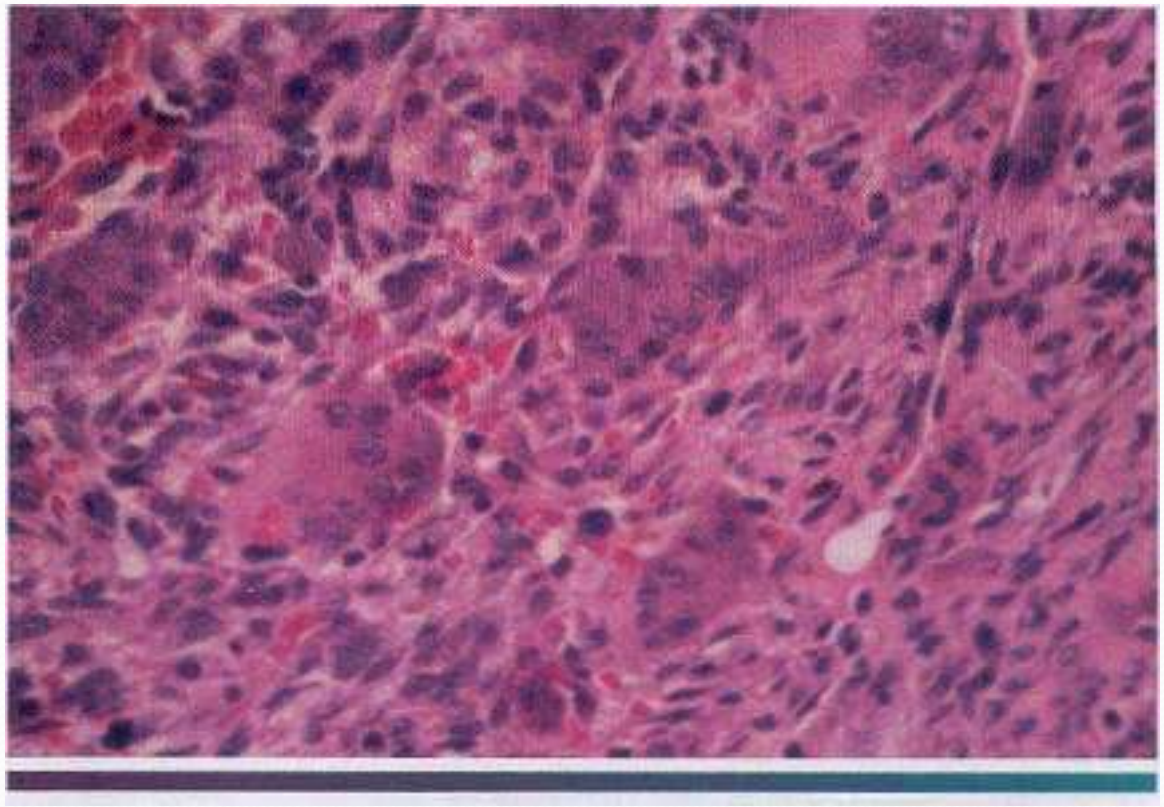

**Hyperparathyroidism: Low-power photomicrograph shows delicate, interconnecting trabeculae of woven bone within a background of cellular fibrous connective tissue.**

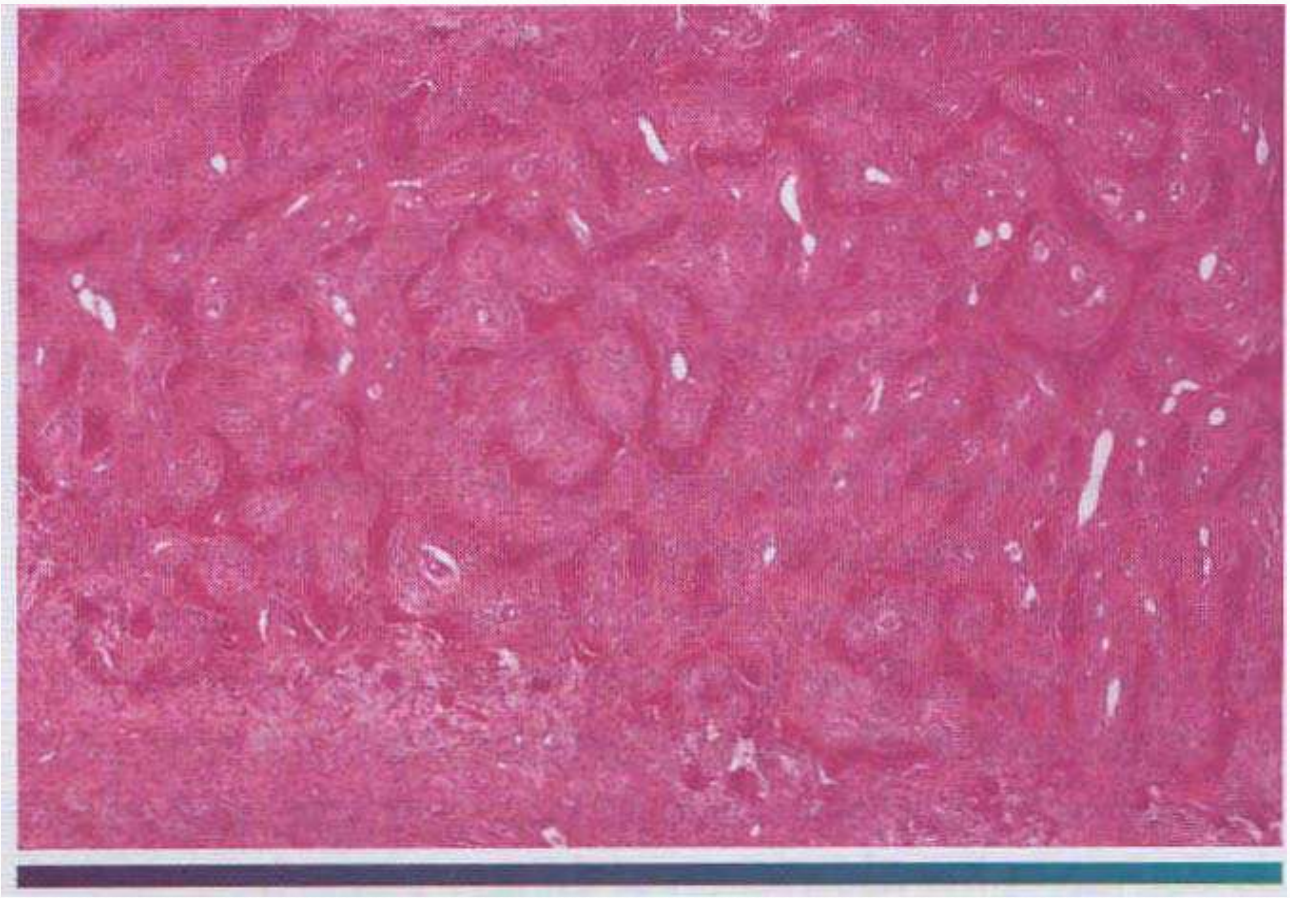

*Thank you*